

# THE EFFECTS OF A HOME-BASED CONNECTIVE TISSUE TARGETING THERAPY ON HIP DEVELOPMENT IN CHILDREN WITH CEREBRAL PALSY: SIX CASE REPORTS

Erika Drewes, MBChB, MMedFamMed<sup>1,#</sup> Mark Driscoll, PEng, PhD<sup>2,3</sup> Leonid Blyum,<sup>3</sup> and Diane Vincentz, Dipl(FH)<sup>4</sup>

Hip subluxation in children with Cerebral Palsy (CP) has an incidence of 10–30 %, and children with severe CP having the highest incidence. The condition deteriorates if left untreated. Surgery is the most common method used in managing hip subluxation because standard conservative therapies do not improve it. Surgery may have to be repeated and comes at a biological cost to the child. A new home-based CAM, Advanced Biomechanical Rehabilitation (ABR), has shown encouraging results leading to improved spinal stability and stability in sitting in children with severe CP. This case report examines hip development over time in six children with severe CP in the

ABR Program. Changes in their clinical picture and pelvic X-Rays are reported. ABR appeared to help stabilize and improve hip subluxation, resulting in these children not requiring further surgical intervention. These findings warrant further investigation of ABR as a noninvasive therapy for hip subluxation.

**Key words:** cerebral palsy, ABR, hip subluxation, complementary and alternative methods

(*Explore* 2016; 12:268-276 © 2016 Elsevier Inc. All rights reserved.)

## INTRODUCTION

Hip dysplasia or subluxation is a common abnormality in hip development in children with cerebral palsy (CP) and has in this population an incidence of 10–30%.<sup>1–6</sup> It is most often diagnosed in children with bilateral CP and the incidence increases with the severity of the condition.<sup>6</sup> There are no conservative measures to prevent the development of hip subluxation in this patient population, therefore, surgery is the most common intervention used. Complementary and alternative medicine (CAM) methods are increasingly used for the treatment of CP. This case series is presented to describe hip development of children with severe CP who are part of a home-based manual CAM therapy program called Advanced Biomechanical Rehabilitation (ABR).

## HIP DEVELOPMENT IN CP

It is thought that abnormal tensional forces around the hip joint, due to lack of weight bearing, spasticity, and contractures lead to the abnormal development of the joint and ultimately to deformities of the bony structures.<sup>1,7,8</sup> Typically, excessive femoral anteversion, posterolateral acetabular dysplasia, and deformation of the femoral head are observed.<sup>7</sup> In addition, flexion-adduction contractures contribute to the displacement of the femur head posterolaterally.<sup>7,8</sup> This displacement is referred to as hip subluxation. Children who never learn to sit independently, are at the greatest risk of developing subluxation that may continue to progress to dislocation if left untreated.<sup>2,3</sup>

Children with CP can, by the time they are three years old, be classified on one of five development curves for gross motor function (GMFSC I-V). Those who fall on the GMFSC III-V (non-ambulant) typically peak in their gross motor function development between the age of six to eight years and thereafter continue to deteriorate functionally and musculoskeletally.<sup>9</sup> Hip subluxation has been shown to be as high as 63% in children in GMFSC level IV or V and that the mean migration percentage per year is 9.5% for GMFSC V.<sup>1</sup>

Therapies such as Botulinum toxin injections and physical therapy programmes, such as bracing, have not yielded encouraging results in the prevention of subluxation.<sup>7,10,11</sup> Botulinum toxin also causes additional changes that impact muscle fiber growth, muscle metabolism, and extracellular matrix formation. The long-term implications of these effects are not fully understood yet.<sup>12</sup> Moreover, the standard neuro-rehabilitative physical therapies on offer, do not appear to prevent musculoskeletal

1 Integrative Family Physician (Private Practice), 15 Budock Road, Claremont, Cape Town 7708

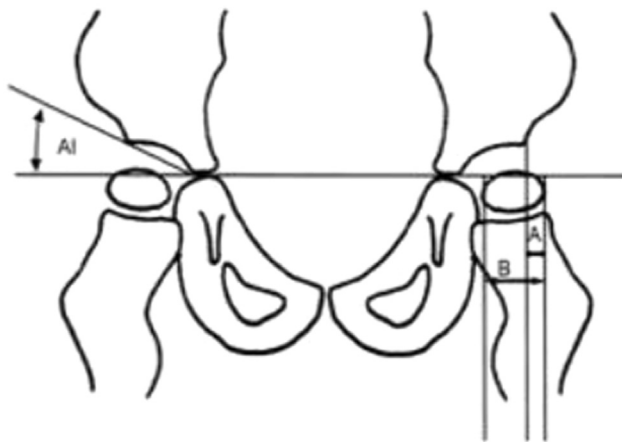
2 Advanced Biomechanical Rehabilitation, Montreal, Pierre-Baillargeons, Canada 11991

3 Biomedical Research Group, 5135 Bessborough St, Montreal, Canada H4V2S5

4 Advanced Biomechanical Rehabilitation, Hornstrupvej 36, Skanderborg 8660, Denmark

# Corresponding author.

e-mail: Erika.drewes@me.com; erikadrewes@gmail.com



**Figure 1.** A line drawing showing the pelvis depicting how the MI is measured. MI is calculated as a percentage  $A/B$  multiplied by 100.

degeneration.<sup>9</sup> Therefore, hip subluxation is largely managed surgically.<sup>7</sup>

Once present, hip subluxation does not typically resolve spontaneously.<sup>3</sup> Untreated hip subluxation often leads to difficulty in nursing activities, poor perineal hygiene, difficulty in walking and mobility, hip joint arthritis, and chronic pain.<sup>1,5-7</sup>

### DIAGNOSIS, SCREENING, AND MANAGEMENT OF HIP DISORDERS IN CP

Most developed countries have instituted hip screening programmes for their CP affected populations. Hereby all children with a risk of hip subluxation are radiographed at regular intervals to assess the condition of the hip joints. The measurement of the migration index (MI) percentage has been shown to be the most accurate and effective index in determining the children who are at the greatest risk of developing hip dislocation.<sup>13</sup> MI measurement determines by how much the femoral head is displaced laterally and is done by calculating percentage of the femoral head area that is not covered by the acetabulum as observed in Figure 1 of an anterior-posterior pelvic X-ray<sup>1</sup> (Figure 1).

This measurement is reported to have the least variance between observers and is not influenced greatly by small differences in the patients' positioning at the time of X-ray.<sup>6</sup> Patients with femoral head displacement or MI > 33%, are said to have hip subluxation.<sup>1,13</sup> Hip subluxation is also assessed clinically by measuring the degree of hip abduction, pain, and mobility. At least one-third of hip joints with a MI of more than 50% will progress to further subluxation,<sup>3</sup> while hips with an MI of between 60% and 90% all go on to dislocation.<sup>3,4,6</sup> Surgery is generally recommended above 33% in Europe and 40% in North America.<sup>1,8</sup>

### SURGERY FOR HIP SUBLUXATION IN CP

Surgery for hip subluxation has evolved over the past decades from being invasive and radical procedures done later in the

child's life to currently less invasive procedures (soft tissue lengthenings) done at younger ages.<sup>8</sup> The rationale of this approach is to prevent further subluxation and bone deformities while minimizing the biological cost to the child due to surgery.<sup>8</sup> Early soft tissue release surgeries have, however, been reported to result in high reoperation rates due to recurrent subluxation.<sup>7</sup> Selective percutaneous myofascial lengthening surgery has been reported to yield encouraging results; however, further evidence is needed.<sup>14</sup> In addition, these surgeries have not yet been shown to prevent joint deformities. While coverage of the femoral head somewhat improves post-operatively, acetabular remodeling does not.<sup>5</sup>

Studies measuring the long-term outcomes of surgery for hip subluxation are sparse and few report on hip pain outcomes and quality of life post-surgery.<sup>4,7</sup> Prognostic indicators for future pain due to hip subluxation also do not exist.<sup>8</sup> One prospective study did report significant improvement in quality of life after hip surgery,<sup>15</sup> but did not comment on joint pain. Other authors report that patients who had undergone soft tissue releases were just as likely, as those who had not been treated, to have pain.<sup>7</sup>

Long-term studies that measure improved motor function, such as sitting or walking after surgery are few.<sup>7,14</sup>

### TISSUE CHARACTERISTICS IN CP

Connective tissue is currently being studied worldwide. Its impact on the motor function of the body was previously thought to be negligible. This view is now being challenged by new data.<sup>16</sup> It has been shown that connective tissue acts as a tensional, load-bearing tissue that is capable of contracting independently of muscular contraction.<sup>16,17</sup> The connective tissue functions within a specific mechanical tensional range. When this tensional range is physiologically optimal, the connective tissue not only plays an important role in transmitting forces between muscles, but can also adjust structurally in order to control an inflammatory environment.<sup>17,18</sup> In this regard, fibroblasts, the dominant cell type in the connective tissue, play a significant role. These cells have been shown to communicate with each other via gap junctions.<sup>16</sup> This means that connective tissue forms a mechanosensitive signaling system that penetrates the whole body to the same degree as the nervous system.<sup>16,18</sup>

Studies have found persistent pro-inflammatory responses in infants and children with CP compared with healthy children.<sup>19,20</sup> Biopsies of contracted skeletal muscle tissue in children with CP have been reported to have increased levels of various inflammatory and pro-inflammatory cytokines.<sup>21</sup>

Studies demonstrate that fibroblasts regulate the switch between acute and chronic inflammatory immune responses in the body.<sup>22,23</sup> During acute inflammation, the connective tissue typically becomes dense. If the inflammatory conditions persist, the densification becomes permanent and is then defined as fibrosis.<sup>17,24,25</sup> Clinically, such tissue is appreciated as being stiff and with diminished pliability.<sup>18</sup> Shortened and stiff connective tissue can cause pain in sensitive areas such as the areas around neuromuscular bundles when subjected to stretch. Such tissue is also weaker than healthy connective tissue, and therefore impacts motor function. Altered connective tissue mechanics

---

can have widespread effects that go beyond compromised motor function and pain. These include altered immune function, abnormal cellular metabolism, and altered gene expression patterns.<sup>17</sup>

After injury, or during inflammation, it has been noted that fibroblasts with smooth muscle-like cell features, known as myofibroblasts, increase in the area. Myofibroblasts are able to contract and pull together the edges of a wound. After wound closure, they typically decrease in number through apoptosis. With persistent inflammation, myofibroblasts do not apoptose, which are associated with a spectrum of fibrotic conditions.<sup>16</sup>

Several studies have been published discussing changed extracellular matrix (ECM) properties of the connective tissue that result in altered joint moments and load-bearing pathways.<sup>24,26,27</sup> Smith et al.,<sup>28</sup> have demonstrated that the most mechanically impactful skeletal tissue changes in tissues samples of children with CP are those that take place in the ECM.<sup>29,27</sup> On histological examination of skeletal muscle, there is more collagen, increased myofibroblasts, increased inflammatory cells, and myofibrillar disorganization present in the matrix.<sup>17,24,25,28</sup> These tissue changes have been ascribed to altered mechanical properties, altered inflammatory environments and gene expression pathways and are mediated by various factors like transforming growth factor-beta1 (TGF $\beta$ ) signaling.<sup>21,24</sup> TGF $\beta$  is associated with fibroblast conversion into myofibroblasts, thereby contributing to tissue fibrosis.<sup>25</sup> The cumulative result is increased tissue stiffness which, in turn, impacts joint moments and joint development.<sup>27</sup> Stiff ECM as found in CP, has been shown to have less capacity to bear tensile loads compared to ECM of healthy patients.<sup>28,27,30</sup>

Skeletal muscle cells are also altered in individuals with CP. Muscles are generally shortened in CP compared to healthy children.<sup>12,14</sup> Reduced strength has also been a noted feature of muscle fibers in CP.<sup>28,26</sup> Sarcomere lengths of biopsies of the semitendinosus and gracilis muscles in children with CP were found to be increased during rest.<sup>28</sup> The morphological changes found in biopsy analyses of CP skeletal muscle have been connected to up-regulated insulin-like growth factor 1 and myostatin.<sup>28</sup> Myostatin is known to inhibit muscle fiber growth while insulin-like growth factor stimulates protein synthesis and ultimately muscle development through pathways that involve mammalian target of rapamycin (mTOR).<sup>12,31</sup>

Driscoll and Blyum<sup>29</sup> have discussed a model of how irregular muscle activation, in degenerative diseases such as CP, leads to tissue remodeling and subsequent musculoskeletal deterioration. Gough and Shortland<sup>12</sup> have suggested that impaired growth and altered development of muscle contribute to the development of deformity.

While the increased stiffness and repetitive mechanical strain seem to reinforce fibrotic-like change and musculoskeletal deterioration, other studies have shown that mechanical stretching of connective tissue and skeletal muscle cells could decrease inflammatory cytokines, influence cell responses and change tissue turnover.<sup>32–35</sup> Mechanical stimulation of connective tissue using manual therapy techniques, therefore, becomes relevant not only for a neuro-rehabilitative effect, but also for a connective tissue remodeling effect.

## CAM EFFECTS ON CONNECTIVE TISSUE AND CP

CAM does not typically form part of mainstream treatment approaches for CP, but is increasingly utilized by families and medical workers seeking additional therapy for their cerebral palsy affected patients.<sup>36,37</sup> Herbal remedies, hyperbaric oxygen, cranio-sacral therapy, and manual therapy all form part of this therapeutic group.<sup>37</sup> Myofascial releases, attained by one or a combination of acupuncture, manual therapy, trigger point release (TPR), advanced biomechanical rehabilitation (ABR), and osteopathy are of particular interest. While these manual therapies differ in the actual delivery technique, the type of tissue that is targeted is the connective tissue.<sup>36,37</sup> The clinical effects of manual therapies have been studied more extensively in adult patients compared to pediatric populations. However, a few case reports describe that therapies like acupuncture, osteopathy, and TPR therapy improve load-bearing capacity and joint mobility while they also reduce pain, tone, and spasticity in children.<sup>36–38</sup> ABR, has also recently been reported to improve quality of life and motor function in children with severe CP (GMFSC IV and V).<sup>39</sup> While these findings are encouraging, the effects of such therapies on hip development in CP are currently unknown.

The exact mechanism by which manual therapy effects healing in the tissue (*fascial plasticity*) has not been confirmed and remains under researched.<sup>18,36</sup> Several mechanisms have been proposed in the literature and are being considered in in-vitro and animal studies.<sup>38</sup> Human patellar fibroblasts subjected to mechanical stretching underwent immunological changes that appeared to increase cell proliferation, differentiation, and matrix formation.<sup>34,40</sup> Mechanical stretching has also been shown to help regulate inflammatory responses in muscle tendons.<sup>21,40,32</sup> Stretching tissue briefly has been shown to decrease TGF $\beta$ 1-mediated fibrillogenesis.<sup>16</sup> Mechanical stimulation of skeletal muscle cells has uniquely been shown to induce mTOR, a protein complex that seems to regulate protein synthesis and muscle growth.<sup>31,35</sup> These mechanisms, however, require further investigation.<sup>12,35</sup> Fascial plasticity has been ascribed to piezoelectricity.<sup>38</sup> This kind of manual mechanical stimulation is theorized to result in a higher electric charge in the tissue, which is thought to stimulate fibroblasts into producing new collagen in that area.<sup>38</sup> Bone remodeling after a fracture and wound healing has previously been shown to follow a similar process. Another model for *fascial plasticity* has been proposed to be via a neurobiological pathway.<sup>38,41</sup> Hereby the manual therapist stimulates remodeling of the fascia through manual stimulation of mechanoreceptors and interstitial muscle receptors that are present in the muscle septae and tendons. It has been proven that slow deep pressure to tissues result in decreased muscle tone as measured by EMG as well as increasing vagal tone.<sup>41</sup> The in vivo effects of manual therapies on human cellular mechanisms (such as mTOR or fibroblasts) in CP have as yet not been reported.

## ABR AND HIP DEVELOPMENT IN CP

ABR is a home-based manual therapy that trains parents to deliver stimulation to the connective tissues through various

manual techniques. It is gentle, non-invasive, and can be delivered manually or by using a massage machine connected to the patients. The manual techniques are a combination of compression and stretching applications delivered through a variety of media. These include soft pads, sponges, folded towels, or balls. These materials facilitate delivery of the therapy and ensure patient safety. ABR is the only manual therapy that has been specifically designed for children with CP in mind.

A prospective cohort study of 100 children in the ABR program over 3 years showed significant improvement of the CPCHILD questionnaire in children with GMFSC levels IV and V suggested improvement of health and well-being.<sup>39</sup> In addition, it was shown that ABR significantly increased spinal stability of the patients. This stability clinically resulted in the improved ability to sit. The GMFSC classification of children in level V changed to GMFSC level IV by the end of the study.<sup>42</sup> Given these gains in motor function, especially the improvement in ability to sit, makes it interesting to report on the impacts ABR might have on the hip joints. Hip subluxation is most likely to affect children who do not attain sitting.<sup>2,3</sup> The improved ability to sit might, therefore indicate improved hip joint dynamics. It is hypothesized that ABR would lead to improved hip joint function, and therefore improvement of hip subluxation.

This article reports on a study done on six children in the ABR Program with regards to their hip development and pelvic X-rays while receiving ABR.

## METHODS

### Patient Selection and Data Collection

Six children who were in the ABR Program were recruited for this case report. Parents had to consent in writing to sharing the pelvic X-rays taken as part of routine hip screening and to an interview detailing the clinical history of their child. There were no exclusion criteria. Ethical approval was obtained from the Committee for Scientific Ethics in Region Mid Jylland, Denmark.

### Materials and Measurements

The X-rays of each child were collected and numbered. The X-ray data were blinded from the investigator who did the MI measurements for each X-ray. The investigator was also

blinded to the child's clinical history and when it started in the ABR program.

The parents of each child were then interviewed regarding the clinical history of each child to complete the analysis.

### The ABR Method

Typically, caregivers of children in the ABR program are instructed in the ABR method by an experienced physical therapist over a three-day training course. The methods are designed to be safe and simple and are aimed at providing passive manual stimulation to the core (neck, thorax, abdomen, and pelvis) of the child's body. These methods manually provide a gradual pressure increase to 20–25 in H<sub>2</sub>O over 30 seconds which is then released over the following 10 seconds. A custom force gauge, integrated into the therapy, helps to support very specific instruction in magnitude and frequency of and ABR stimulation. Very simply put, the caregivers are taught how to apply a specific and safe downward pressure to the patient's body in a cyclical application. After each force of pressure applied, a release over 10 seconds takes place before the next application of pressure. A therapeutic machine, developed by the ABR team, can alternatively be connected to the child's body to provide the aforementioned stimulation without needing manpower. The training course of three days typically takes place at baseline and is then repeated every six months. This repetition allows for verification of the caregivers' techniques and also allows for adjustments in the various ABR methods as the child's structure evolves over time. The caregivers do the stimulation at home and are usually asked to aim for one hour a day. A recent study found that most parents were able to work for longer periods of time than requested by the study protocol. This led them to conclude that ABR was well taken up by caregivers.

A short video that shows footage of the ABR approach, a typical scene where parents are trained, a typical ABR construction and technique with ball and soft pads and more before and after video material of children with various types and degrees of CP can be viewed under <https://vimeo.com/64683268>.

### Results: Blinded X-ray MI Measurements Over Time

The blinded MI measurement findings for the individual cases are summarized in Table 1 with Table 2 summarizing the average MI measurements over time. The measurements clearly show a reduction in MI measurement over time.

**Table 1.** Individual MI Measurements Over Time

Time (years)	Patient 1		Patient 2		Patient 3		Patient 4		Patient 5		Patient 6		Average	
	L (%)	R (%)	L (%)	R (%)	L (%)	R (%)	L (%)	R (%)	L (%)	R (%)	L (%)	R (%)	L (%)	R (%)
0.0	65	26	36	49	35	39	16	22	17	74	26	44	33	42
0.5					43	28			13	50			28	39
1.0	83	27	27	43	42	49	22	15	9	36	31	36	36	34
1.5					30	38							30	38
2.0	24	30			32	28			20	60			25	39
2.5	15	32			40	41							28	36
3.0	14	39					10	4	32	38			19	27

The data depict the changes in the MI for both hips in each of the patients over time (years) with 0.0 indicating the baseline measurement.



**Table 2.** Summary of MI Average Over Time

Timeline Summary		
L (%)	R (%)	Time (years)
33	42	0
34	35	1
24	37	2
24	30	3

The data depict the average change in MI in each hip of each over time.

When the averages are plotted graphically (Figure 2), the trend of MI reduction becomes apparent.

### Results: Patient Case Histories

**Patient 1.** Patient was an eight-year-old (DOB: 16.06.2006) girl with spastic quadriplegic CP following a premature birth at 26 weeks of pregnancy (Figure 3). She was diagnosed with CP at seven months of age and is GMFSC level IV. She is also blind in the right eye with severe nystagmus and impaired vision of the other eye. She is on no medication. Initially she attended NDT/Bobath physiotherapy and occupational therapy. In December 2009, she started with ABR therapy in addition to physiotherapy and occupational therapy once a week. The parents worked one and half hours per day with the ABR machine applied at night. In June 2010, she was diagnosed with bilateral hip subluxation and in February 2010 had soft tissue lengthening surgery to help correct the subluxation of the right hip. At the time, the surgeon predicted reoperation after two years and that the left hip would require surgery inevitably. The family continued with ABR in the years post-operatively. The initial pelvic rays showed the expected post-operative improvement of the right-sided hip. However, there was continuous improvement of both hips. Clinically, the patient also made motor gains that included neck control, trunk control, and hip mobility and she has been able to sit unsupported in tailor sitting since 2013. She has not required any further surgery since 2010.

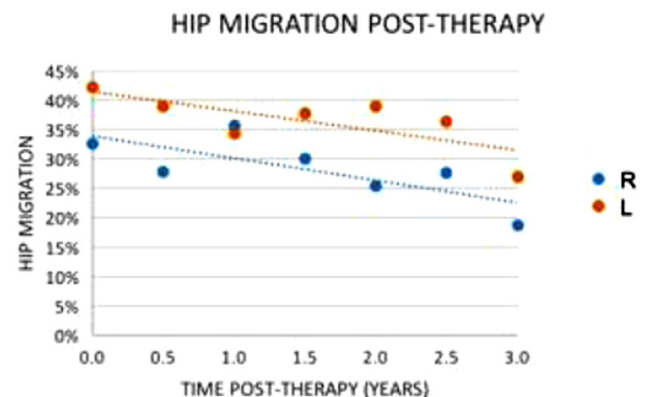
General improvements not related to the hips. The parents reported improved immune function; improved ability to focus her eyes (she is now reading) and needs glasses. The first improvements noted by the parents after starting ABR, was that her ear-position shifted (one ear was located much lower on the head than the other prior to starting ABR) and she needed her glasses adjusted after a few months to a more balanced position.

**Patient 2.** Patient was an eight-year-old boy (DOB: 05.05.2006) with a diagnosis of spastic-dystonic quadriplegic CP that was diagnosed when he was seven-month old (Figure 4). He is GMFSC level III and had epilepsy when he was two and a half. He was medically treated, but was in remission at the time of the study, and therefore not on any medication. After the CP diagnosis, the parents opted for intensive physiotherapy, occupational therapy and later, conductive education. He was receiving therapy for about

five hours a day. The parents felt that the therapies were not improving their child's mobility. The therapists were constantly preventing the child from W-sitting (his preferred sitting position) and were also correcting his bunny-hop crawling. This caused the child unhappiness and frustrated the parents. They decided to try something else. They started with ABR in 2010 and continued for the next two years. The parents were advised to consider hip surgery in 2012, because the pelvic X-rays showed hip subluxation. The parents declined the surgery against medical advice and continued with ABR. They continued to monitor the situation clinically with follow-up X-rays. These have shown improved hip migration percentage and his hip mobility also improved clinically. The child has subsequently been discharged from the hip X-ray surveillance program and only needs clinical follow-up every second year.

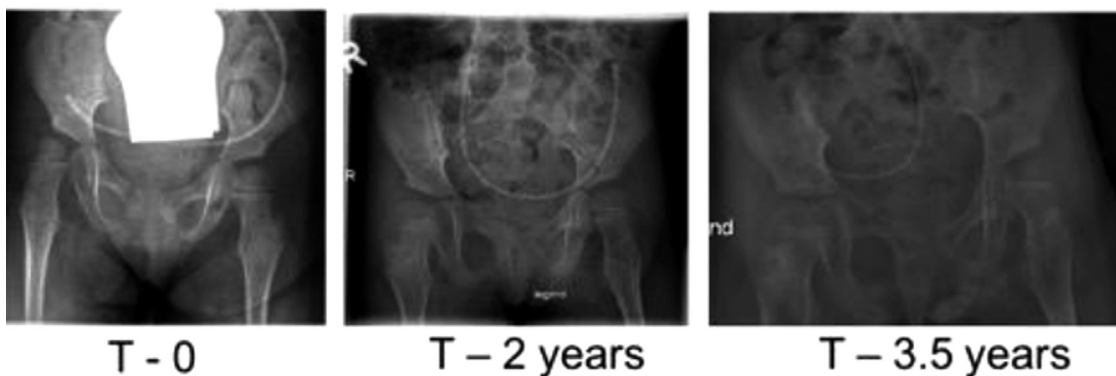General improvements not related to the hips: The parents reported improvement of his general health status since he started ABR. The parents also attributed the remission of his epileptic seizures to ABR. His speech also improved. Before ABR he spoke, but his articulation was unclear. After ABR, they reported, his speech became much clearer.

**Patient 3.** Patient was an eight-year-old girl (DOB: 19.04.2006), born prematurely at 32 weeks gestation. The post-natal period was hallmarked by feeding difficulties, apnea and a staphylococcal infection. She was diagnosed with quadriplegic, spastic CP and is now classified at GMFSC III. The parents have done many various therapies since 2007. These include Doman method (2007–2009), Feldenkrais/Anat Baniel Method (2009–present), Temprana (2014–present), and ABR (2008–present). This patient was 18-month old when she started ABR and the parents report that she could not move her arms or spine at all before they started ABR. The changes they observed in her, since commencing ABR, were improved mobility of the upper body, spine, and abdomen and hand function. She is now able to come into high kneeling from the floor and maintain this position for long periods of time. She can crawl and play independently on the floor. Her leg adductors are still quite tightened. The family have been advised



**Figure 2.** Average MI trend over time.

## Patient 1



**Figure 3.** The pelvic X-rays of patient 1 over three years (T = time in years.)

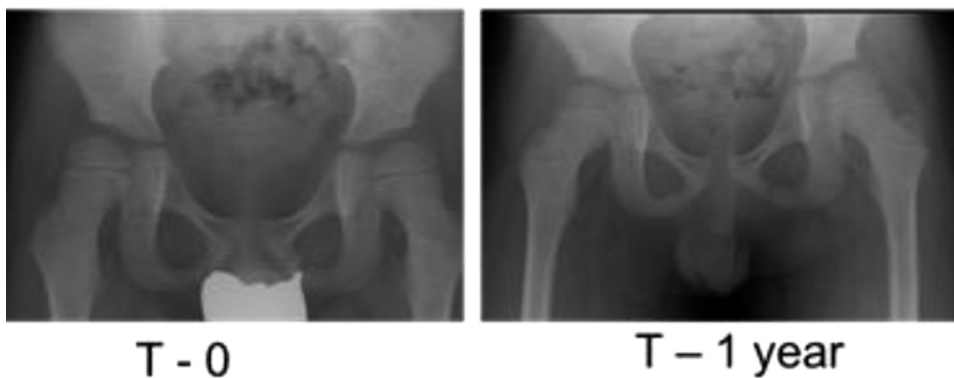to have surgery for hip subluxation despite her improved clinical condition.

General improvements not related to the hips: Improved cognitive ability, clarity of speech, improved fine motor function, and improved balance. The mother attributes all

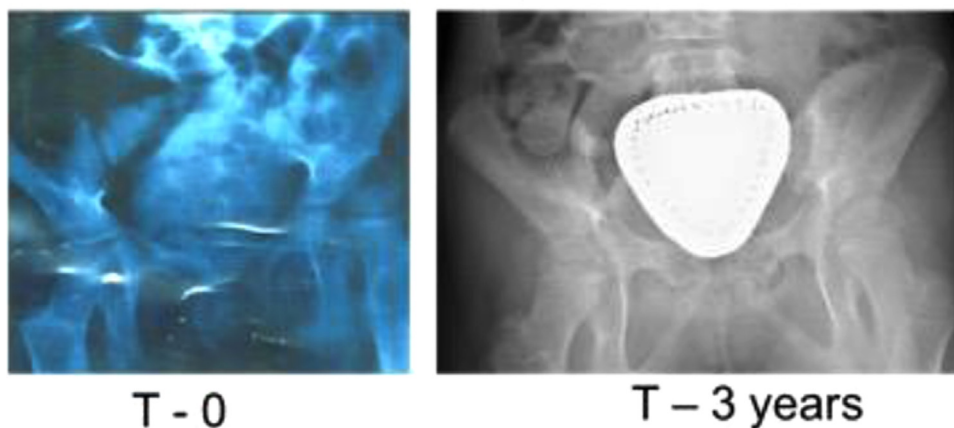
these changes to the ABR. She drives her own wheelchair. This family opts to do ABR three to four hours per day.

**Patient 4.** Patient was a 10-year-old child (DOB: 1.12.2003) with quadriplegic CP and GMFSC IV. He was diagnosed with

## Patient 2



## Patient 5



**Figure 4.** Before and after X-rays for patients 2 and 5 over time (T = time in years).

CP at birth since he was born prematurely and had severe periventricular leucomalacia (PVL) on the early brain imaging studies. He is also mentally handicapped. He takes Macrogol for constipation, but no other drugs. He started ABR in 2006, but also receives physiotherapy (NDT/Bobath), occupational therapy, Feldenkrais therapy, and hippotherapy on a weekly basis. The child also uses a NF walker for training at home and has a standing frame. The mother does ABR manually for about one hour a day and uses the ABR machine at night. In 2008, the parents were advised that he needed hip surgery to prevent further hip subluxation, but they declined. Subsequent films showed continuous improvement and on the last visit, the surgeon suggested that no surgery was indicated at the time. He suggested that the hip improvements were due to the standing frame.

General improvements not related to the hips. The mother said the most dramatic improvement after starting ABR was the decrease in recurrent chest infections. His overall trunk stability improved and his spine straightened. In addition, there was an obvious improvement noticed in his cognitive abilities.

**Patient 5.** Patient was a seven-year-old girl (03.05.2007) with quadriplegic CP and due to hypoxic ischemic encephalopathy at birth. She was classified as GMFSC V (Figure 4). Between 2007 and 2009 she had had a Gastrostomy, Nissen fundoplication, and a hiatus hernia repair for gastroesophageal reflux disease. She is fed orally and also via her gastric tube. She received NDT, Conductive Education and Feldenkrais over the years between 2008 and 2012. When she was three years old (2010) she had developed hip problems (her left hip was clicking and she had pain.) She was not making any progress in her motor development. She was diagnosed with bilateral hip subluxation in 2010 and surgery was recommended. The family had just started in the ABR program and decided to defer surgery while they tried to improve the subluxation with ABR. It was agreed to monitor the pelvic X-rays every six months to assess if the situation improved. The X-rays remained unchanged at first and then started showing improvements. The orthopedic surgeon currently does not recommend surgery. She is now classified as GMFSC 4.

General improvements not related to the hips: The family have noted improved immunity (fewer chest infections), improved cognitive ability, improved motor (gross and fine), and improved communication skills. She is currently in a mainstream school with supported teaching. They attribute all of her gains to ABR.

**Patient 6.** A patient was a two-year-old girl (DOB: 15.12.2012), who developed polymicrogyria, lissencephaly, and microcephaly secondary to an antenatal Cytomegalovirus infection. Clinically she has quadriplegic CP GMFSC level IV. Initially, the family started with Bobath/NDT and Vojta therapy, but discontinued it in 2014. She was diagnosed with hip subluxation in November 2013. Botulinum toxin was injected in her arms and also in the leg adductors on December 2013, April 2014, and October 2014. Since then

she has not had any. The surgeons, who were managing her care, advised the injections to prevent further deterioration since they did not believe improvement of the subluxation was possible. In June 2014, they started with osteopathy and ABR. The family worked about two hours per day with ABR. Subsequent pelvic films showed significant improvement after the family decided to start with ABR and Osteopathy. The family noticed improved hip range of movement and decreased tone in her body. She is also feeding better with an improved ability to swallow.

## DISCUSSION

Children with severe CP are expected to develop progressive hip subluxation that does not typically improve without surgical intervention.<sup>1</sup> In five of the cases (Patients 2–6), evidence of subluxation improvement without surgical intervention was found. Although one of the children, Patient 1, had had soft tissue release surgery shortly after starting ABR, the findings still remain encouraging. The relevant literature<sup>5,7</sup> suggests that even with surgery one would have expected progressive deterioration of the joint in someone with her degree of CP.

ABR is a home-based therapy that empowers parents to relieve spasticity and improve their child's motor function without requiring any physical performance from their child. Studies have found that depression and helplessness occur less frequently in parents of children with disabilities when they feel they are empowered to cope in the situation they are in.<sup>43</sup> Thus, ABR aligns well with the current trend to empower parents of children with CP with home-based therapies.

ABR utilizes simple manual tissue stimulation methods using soft pads and balls that trained parents can easily and safely apply at home. This delivery technique allows for children to be treated regardless to the distance they live away from expert care centers. Moreover, children who live in developing countries usually face many barriers to care such as travel distance and limited access to surgical services.<sup>44</sup> ABR could be an answer in low resource settings such as these.

The primary causes of hip subluxation can possibly be attributed to abnormal or lack of weight bearing, muscle underdevelopment, and inappropriate irregular nerve stimulation that result in disrupted forces around the hip joint.<sup>7,12,28</sup> While these explanations may be true, it is also true that disrupted physiological tension, as delivered via the connective tissue matrix around joints, would cause additional disruptive effects on joint moments and subsequent joint development.<sup>12,27,45</sup> Current surgical interventions, such as soft tissue release surgery, targets specific anatomical structures (e.g., specific joints, tendons, or nerves) and do not necessarily stimulate connective tissue development.<sup>45,46</sup> New data suggest that connective tissue should be therapeutically appreciated as a body-wide organ system.<sup>47</sup>

ABR techniques applied to the neck and trunk resulted in the significantly increased intra-abdominal compressional strength and the increased stability of the middle third of the vertebral column.<sup>42</sup> These findings were directly

correlated with the participants' improved ability to maintain a sitting position, possibly indicating improvements in pelvic stability or hip joint dynamics. This could be the possible mechanism through which the hip subluxation, improves as presented in this case report.

The general gains in immune function, cognitive development, respiration, and metabolism as reported by the parents may indicate improved tissue metabolism and homeostasis. To investigate these findings further, it would be important to study the impacts of manual therapy (in this case ABR) on the connective tissue network. Studies on skeletal muscle changes in CP have shown that the ECM is formed disproportionately to skeletal muscle cells when compared to healthy tissue samples of typically developing children.<sup>24,28,26</sup> This appears to be caused by altered gene expression patterns that are immunologically and mechanically mediated.<sup>22,25,34,40,32</sup> The authors conclude that the mechanical stimulation the myofascial tissue by ABR could induce epigenetic, immunologic, and metabolic changes that allow for the ECM to be generated in a more physiological way. This would account for the body-wide structural, immunological, and metabolic changes observed in the children included in this report. Further investigation into the physiological effects of ABR is, however, needed to understand these possible effects fully.

## CONCLUSIONS

When correctly stimulated, connective tissue may over time, remodel into more elastic tissue that is able to stretch and bear loads more effectively.<sup>36,38,41,47</sup> The exact mechanisms by which this remodeling takes place could make for interesting future studies. It would appear, from the findings discussed here, that the cyclical mechanical tissue stimulation of the ABR techniques has a similar remodeling effect as reported in animal and in-vitro studies.

The findings of this report are consistent with a recent study on the effects of ABR and other connective tissue targeting therapies on children with CP.<sup>36,37,39</sup> While this is only a case report series of six cases, the results warrant further investigation. They indicate that ABR could turn children, who require surgery for hip subluxation, into children who do not (Figure 1).

The impact of a home-based therapy on the connective tissue structure in children with brain injury opens new treatment possibilities, especially for children with GMFSC III-V CP. More study is urgently needed on the tissue changes that take place in children with CP when receiving manual therapies such as ABR.

## Acknowledgment

We would like to acknowledge the families who participated in this case report. Without them, the study would not have been possible. This study was privately funded. ABR Denmark offered reimbursement of costs to the participating families for obtaining copies of the X-rays and postage.

## REFERENCES

1. Terjesen T. The natural history of hip development in cerebral palsy. *Dev Med Child Neurol.* 2012;54(10):951–957.
2. Pountney TE, Mandy A, Green E, Gard PR. Hip subluxation and dislocation in cerebral palsy—a prospective study on the effectiveness of postural management programmes. *Physiother Res Int.* 2009;14(2):116–127.
3. Flynn JM, Miller F. Management of hip disorders in patients with cerebral palsy. *J Am Acad Orthop Surg.* 2002;10(3):198–209.
4. Miller F, Bagg MR. Age and migration percentage as risk factors for progression in spastic hip disease. *Dev Med Child Neurol.* 1995;37(5):449–455.
5. Schmale GA, Eilert RE, Chang F, Seidel K. High reoperation rates after early treatment of the subluxating hip in children with spastic cerebral palsy. *J Pediatr Orthop.* 2006;26(5):617–623.
6. Kim SM, Sim EG, Lim SG, Park ES. Reliability of hip migration index in children with cerebral palsy: the classic and modified methods. *Ann Rehabil Med.* 2012;36(1):33–38. <http://dx.doi.org/10.5535/arm.2012.36.1.33>.
7. Stott NS, Piedrahita L, AACPDM. Effects of surgical adductor releases for hip subluxation in cerebral palsy: An AACPDM evidence report. *Dev Med Child Neurol.* 2004;45(9):628–45.
8. Portinaro N, Panou A, Gagliano N, Pelillo F. DDSH: developmental dysplasia of the spastic hip: strategies of management in cerebral palsy. A new suggestive algorithm. *Hip Int.* 2009;19(1):S69–S74.
9. Rosenbaum PL, Walter SD, Hanna SE, et al. Prognosis for gross motor function in cerebral palsy: creation of motor development curves. *J Am Med Assoc.* 2002;288(11):1357–1363. <http://jama.ama-assn.org/cgi/content/full/288/11/1357>.
10. Willoughby K, Ghee Ang S, Thomason P, Graham HK. The impact of botulinum toxin A and abduction bracing on long-term hip development in children with cerebral palsy. *Dev Med Child Neurol.* 2012;54(8):743–747. <http://dx.doi.org/10.1111/j.1469-8749.2012.04340.x>.
11. Mukund K, Mathewson M, Minamoto V, Ward SR, Subramaniam S, Lieber RL. Systems analysis of transcriptional data provides insights into muscle's biological response to botulinum toxin. *Muscle Nerve.* 2014;50(5):744–758. <http://dx.doi.org/10.1002/mus.24211>.
12. Gough M, Shortland AP. Could muscle deformity in children with spastic cerebral palsy be related to an impairment of muscle growth and altered adaptation? *Dev Med Child Neurol.* 2012;54(6):495–499. <http://dx.doi.org/10.1111/j.1469-8749.2012.04229.x>.
13. Häggglund G, Lauge-Pedersen H, Persson M. Radiographic threshold values for hip screening in cerebral palsy. *J Child Orthop.* 2007;1(1):43–47. <http://dx.doi.org/10.1007/s11832-007-0012-x>.
14. Mitsiokapa EA, Mavrogenis AF, Skouteli H, et al. Selective percutaneous myofascial lengthening of the lower extremities in children with spastic cerebral palsy. *Clin Podiatr Med Surg.* 2010;27(2):335–343. <http://dx.doi.org/10.1016/j.cpm.2009.12.005>.
15. Narayan UG, Lochab J, Okusanya OO, Wier S. University of Toronto. The CPCHILD® questionnaire is sensitive to change following hip surgery in children with severe cerebral palsy. In: *32nd European Pediatric Orthopaedic Society, EPOS (poster Presentation)*; 2013.
16. Benjamin M. The fascia of the limbs and back—a review. *J Anat.* 2009;214(1):1–18. <http://dx.doi.org/10.1111/j.1469-7580.2008.01011.x>.
17. Bordoni B, Zanier E. Clinical and symptomatological reflections: the fascial system. *J Multidiscip Healthc.* 2014;7:401–411.
18. Findley T, Chaudhry H, Stecco A, Roman M. Fascia research—a narrative review. *J Bodyw Mov Ther.* 2012;16(1):67–75. <http://dx.doi.org/10.1016/j.jbmt.2011.09.004>.



19. Kapitanović Vidak H, Ivković TC, Jokić M, Spaventi R, Kapitanović S. The association between pro-inflammatory cytokine polymorphisms and cerebral palsy in very preterm infants. *Cytokine*. 2012;58(1):57–64. <http://www.elsevier.com/locate/issn/10434666>.
20. Lin CY, Chang YC, Wang S-T, Lee TY, Lin CF, Huang CC. Altered inflammatory responses in preterm children with cerebral palsy. *Ann Neurol*. 2010;68(2):204–212.
21. Gagliano N, Pelillo F, Chiriva-Internati M, et al. Expression profiling of genes involved in collagen turnover in tendons from cerebral palsy patients. *Connect Tissue Res*. 2009;50:203–208.
22. Buckley CD, Pilling D, Lord JM, Akbar AN, Scheel-Toellner D, Salmon M. Fibroblasts regulate the switch from acute resolving to chronic persistent inflammation. *TRENDS Immunol*. 2001;22(4):199–204.
23. Buckley CD. Why does chronic inflammation persist: an unexpected role for fibroblasts. *Immunol Lett*. 2011;138(1):12–14.
24. Lieber RL, Ward SR. Cellular mechanisms of tissue fibrosis. 4. structural and functional consequences of skeletal muscle fibrosis. *Am J Physiol Cell Physiol*. 2013;305(3):C241–C252. <http://www.ajpcell.org>.
25. Kendall RT, Feghali-Bostwick CA. Fibroblasts in fibrosis: novel roles and mediators. *Front Pharmacol*. 2014;5:1–13. <http://dx.doi.org/10.3389/fphar.2014.00123>.
26. Lieber RL, Runesson E, Einarsson F, Fridén J. Inferior mechanical properties of spastic muscle bundles due to hypertrophic but compromised extracellular matrix material. *Muscle Nerve*. 2003;28(4):464–471.
27. Lieber RL, Fridén J. Spasticity causes a fundamental rearrangement of muscle-joint interaction. *Muscle Nerve*. 2002;25(2):265–270.
28. Smith LR, Lee KS, Ward SR, Chambers HG, Lieber RL. Hamstring contracture in children with spastic cerebral palsy result from a stiffer extracellular matrix and increased in vivo sarcomere length. *J Physiol*. 2011;589(10):2625–2639.
29. Driscoll M, Blyum L. The presence of physiological stress shielding in the degenerative cycle of musculoskeletal disorders. *J Bodyw Mov Ther*. 2011;15(3):335–342. <http://dx.doi.org/10.1016/j.jbmt.2010.05.002>.
30. Thacker BE, Tomiya A, Hulst JB, et al. Passive mechanical properties and related proteins change with botulinum neurotoxin A injection of normal skeletal muscle. *J Orthop Res*. 2012;30(3):497–502.
31. Homberger Ta, Stuppard R, Conley KE, et al. Mechanical stimuli regulate rapamycin-sensitive signalling by a phosphoinositide 3-kinase-, protein kinase B- and growth factor-independent mechanism. *Biochem J*. 2004;380(Pt 3):795–804. <http://dx.doi.org/10.1042/BJ20040274>.
32. Yang G, Im H-J, Wang JH-C. Repetitive mechanical stretching modulates IL-1beta induced COX-2, MMP-1 expression, and PGE2 production in human patellar tendon fibroblasts. *Gene*. 2005;363:166–172.
33. Wang JH-C, Yang G, Li Z. Controlling cell responses to cyclic mechanical stretching. *Ann Biomech Eng*. 2005;33(3):337–342.
34. Skutek M, Van Griensven M, Zeichen J, Brauer N, Bosch U. Cyclic mechanical stretching modulates secretion pattern of growth factors in human tendon fibroblasts. *Eur J Appl Physiol*. 2001;86(1):48–52.
35. Zanchi NE, Lancha AH. Mechanical stimuli of skeletal muscle: implications on mTOR/p70s6k and protein synthesis. *Eur J Appl Physiol*. 2008;102(3):253–263. <http://dx.doi.org/10.1007/s00421-007-0588-3>.
36. Duncan B, McDonough-Means S, Worden K, Schnyer R, Andrews J, Meaney FJ. Effectiveness of osteopathy in the cranial field and myofascial release versus acupuncture as complementary treatment for children with spastic cerebral palsy: a pilot study. *J Am Osteopath Assoc*. 2008;108(10):559–570.
37. Whisler SL, Lang DM, Armstrong M, Vickers J, Qualls C, Feldman JS. Effects of myofascial release and other advanced myofascial therapies on children with cerebral palsy: six case reports. *Explore*. 2012;8(3):199–205.
38. Schleip R. Fascial plasticity—a new neurobiological explanation: part 1. *J Bodyw Mov Ther*. 2003;7(1):11–19.
39. Driscoll M, Blyum L. Investigation of the influence of a home based therapy on the health and well-being of cerebral palsy patients. In: *International Cerebral Palsy Conference, Pisa Italy. Poster Presentation*; 2012.
40. Maeda T, Sakabe T, Sunaga A, et al. Conversion of mechanical force into TGF-beta-mediated biomechanical signals. *Curr Biol*. 2011;21(11):933–941. <http://dx.doi.org/10.1016/j.cub.2011.04.007>.
41. Schleip R. Fascial plasticity—a new neurobiological explanation part 2. *J Bodyw Mov Ther*. 2003;7(1):104–116.
42. Driscoll M, Blyum L. Results of a 3 year prospective cohort study investigating the influence of home-based therapy on cerebral palsy patients GMFCS types 4 and 5. *Dev Med Child Neurol*. 2014;56(s5):67.
43. Hauser-Cram P, Erickson Warfield M, Shonkoff JP, Wyngaarden Krauss M. Children with disabilities: a longitudinal study of child development and parent well-being. *Monogr Soc Res Child Dev*. 2001;66(3):i–viii,1–114. <http://www.jstor.org/stable/3181571>.
44. Donald KA, Kakooza AM, Wammanda RD, et al. Pediatric cerebral palsy in Africa: where are we? *J Child Neurol*. 2015;30(8):963–71. <http://dx.doi.org/10.1177/0883073814549245>.
45. Maas H, Baan GC, Huijting PA. Dissection of a single rat muscle-tendon complex changes joint moments exerted by neighboring muscles: implications for invasive surgical interventions. *PLoS One*. 2013;8(8):E73510. <http://dx.doi.org/10.1371/journal.pone.0073510>.
46. Maas H, Sandercock TG. Force transmission between synergistic skeletal muscles through connective tissue linkages. *J Biomed Biotechnol*. 2010;2010:1–9.
47. Myers TW. *Anatomy Trains*. 2nd ed. New York: Churchill Livingstone Elsevier; 2009.